



โรงพยาบาลสุราษฎร์ธานี

168 ม.3 ต.ด่านซ้าย อ.ด่านซ้าย จ.เลย  
42120

HN : 00070142

Name : นายพล แพทย์โชโย  
Age : 01-01-1967 ( 58 ปี )

Operation Date : 13-01-2568 10:12:33

Treatment Coverage :

AN :

Gender: Male  
Location :

โครงการคัดกรองมะเร็งลำไส้  
(Colonoscopy Screening)

Screening Report (Colonoscopy)

#### ENDOSCOPIST

พญ.จิรวัตร เจียมเจริญ

#### ASSISTANTS

N/A

#### ATTENDENT

PATIENT IN: 10:12:33

OPERATION TIME : 10:12:33 - 11:19:07 ( 66 Minutes )

WITHDRAWAL TIME : - 11:19:07 (679 Minutes)

INSERTION TIME : 10:12:33 - 00000000 ( 612 Minutes )

PLACE : Station01

ENDOSCOPE USED : GIF-1100-OR01 SN 2201520  
[GIF-1100]

BRIEF HISTORY : Screening colonoscopy

INDICATION : CRC screening

ANESTHESIA : IV sedation

MEDICATION : N/A

PRE-DIAGNOSTIC : Screening colonoscopy

BOWEL PREPARATION : Poor

TECHNIQUE : None

#### FINDINGS:

##### Rectum:

A sessile polyp NICE 2 size 20 mm at 15 cm from AV >>> Nss injected with hot snare polypectomy with clip was done.

Descending Colon: A sessile polyp NICE 1 size 5 mm at 80 cm from AV >>> bx was done.

Ascending Colon: 2 sessile polyps NICE 2 size 15 and 20 mm at 110 cm from AV >>> Nss injected with hot snare polypectomy with clip was done.

#### POST-DIAGNOSTIC

K635 Colonic polyp

K621 Rectal polyp

#### PROCEDURE

4523 Colonoscopy

4542 Polypectomy

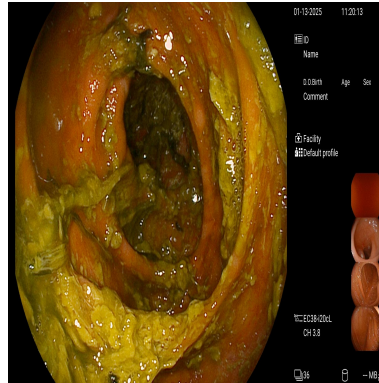
Hemoclip 2 pcs.

COMPLICATION : No Immediate Complication

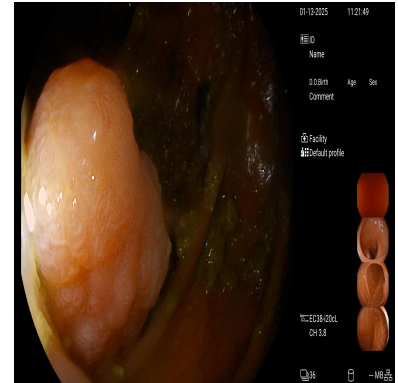ESTIMATED BLOOD LOSS : N/A

BLOOD TRANSFUSION : N/A

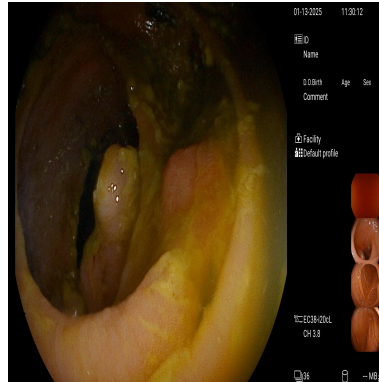
PLAN : N/A



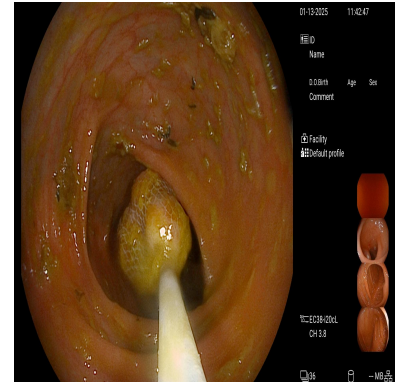
[1]Cecum



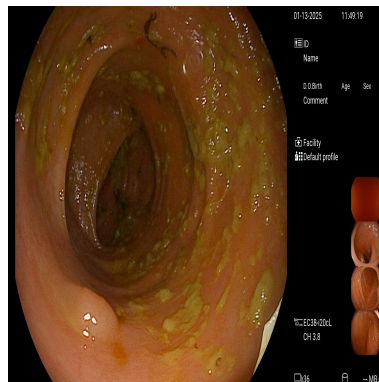
[2]Ascending Colon



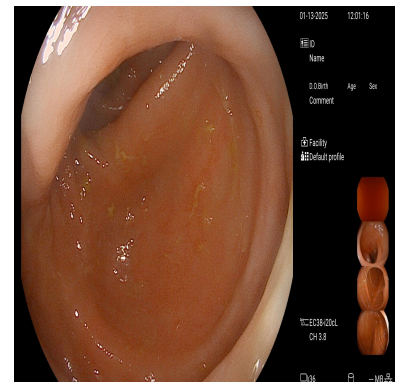
[3]Ascending Colon



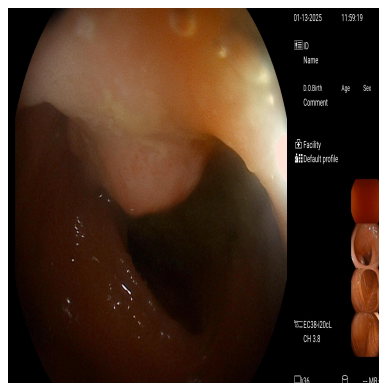
[4]Transverse Colon



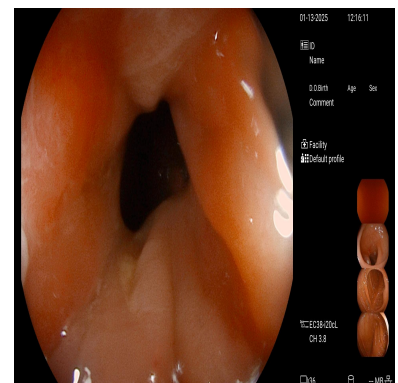
[5]Descending Colon



[6]Sigmoid Colon



[7]Rectum



[8]Anal canal

Signature \_\_\_\_\_ พญ.จิรวัตร เจียมเจริญ

Reported by EndoINDEX