



โครงการคัดกรองมะเร็งลำไส้ (Colonoscopy Screening)
Screening Report (Colonoscopy)

ENDOSCOPIST

ASSISTANTS

ATTENDENT

พญ.อัญญา เกียรติวีระศักดิ์

N/A

PATIENT IN: 13:43:57

OPERATION TIME : 13:43:57 - 14:15:06 (31 Minutes)

WITHDRAWAL TIME : 13:57:23 - 14:15:06 (17 Minutes)

INSERTION TIME : 13:43:57 - 13:57:23 (13 Minutes)

PLACE :

ENDOSCOPE USED : medica SN 00000 [medica]

BRIEF HISTORY :

INDICATION : Fit Positive

ANESTHESIA : N/A

MEDICATION : N/A

Boston Bowel Prep Score : C (FAILURE)

BOWEL PREPARATION : Fair

TECHNIQUE : None

FINDINGS:

Anal canal:

Grade I internal hemorrhoid without bleeding

Rectum:

Unremarkable

Sigmoid Colon:

One sessile polyp NICE II size 5 mm s/p cold snare polypectomy

Descending Colon:

Multiple sessile polyp NICE II size 3-5 mm s/p cold snare polypectomy and One semipedunculated polyp NICE II size 5 mm s/p cold snare polypectomy

Splenic flexure:

Unremarkable

Transverse Colon:

Unremarkable

Hepatic flexure:

Unremarkable

Ascending Colon:

One sessile polyp NICE II size 5 mm s/p cold snare polypectomy

Appendiceal Orifice:

Unremarkable

Cecum:

Unremarkable

Terminal ileum:

Unremarkable

POST-DIAGNOSTIC

K635 Colonic polyp

I842 Internal hemorrhoids without complication

PROCEDURE

4523 Colonoscopy

4542 Polypectomy

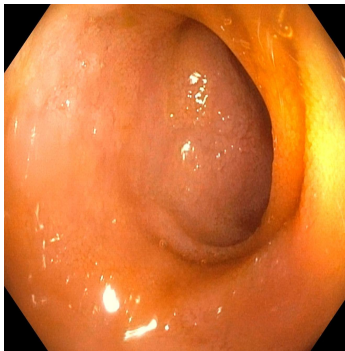
Hemoclip 4 pcs.

COMPLICATION : None Complication

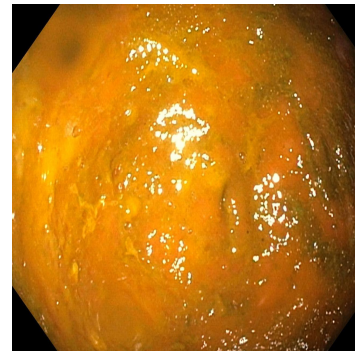
ESTIMATED BLOOD LOSS : N/A

BLOOD TRANSFUSION : N/A

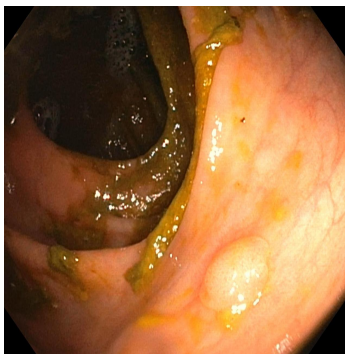
PLAN : N/A



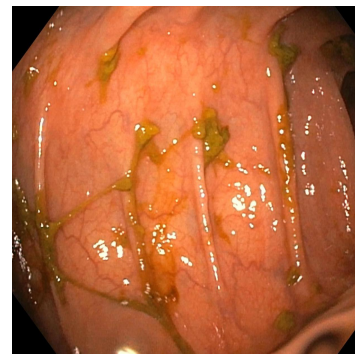
[1]Terminal ileum



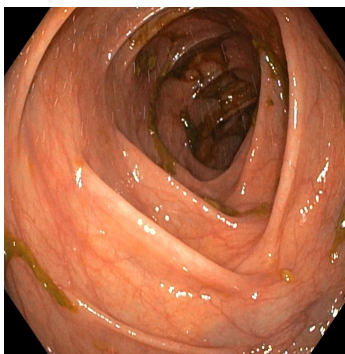[2]Cecum



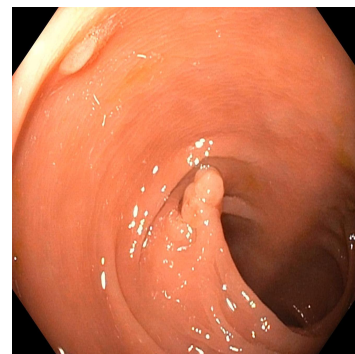
[3]Ascending Colon



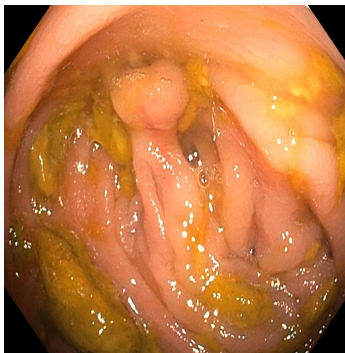[4]Hepatic flexure



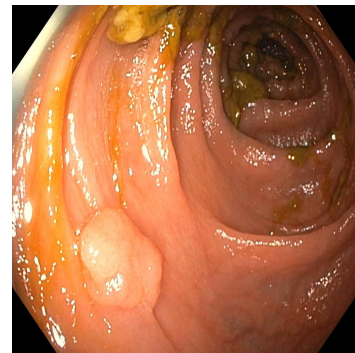
[5]Transverse Colon



[6]Descending Colon



[7]Descending Colon



[8]Descending Colon

Signature

พญ.อัญญา เกียรติวีระศักดิ์

Reported by EndoCAPTURE



โรงพยาบาลเพชรบูรณ์

203 ถ.สามัคคีชัย หมู่ - ตำบล/แขวง ในเมือง อำเภอ/เขต เมืองเพชรบูรณ์
จังหวัด เพชรบูรณ์ 67000

HN : 0986479

Name : นายวันชัย สีทองอ่อน

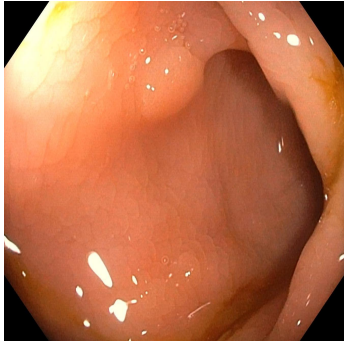
Gender : ชาย

Age : 61 ปี

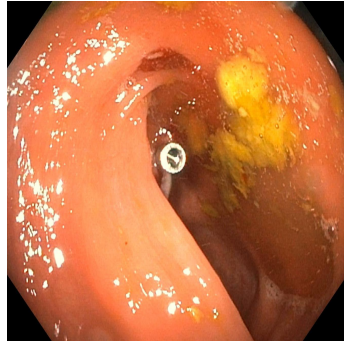
Operation Date : 14-06-2568 (13:43:57)

โครงการคัดกรองมะเร็งลำไส้ (Colonoscopy Screening)

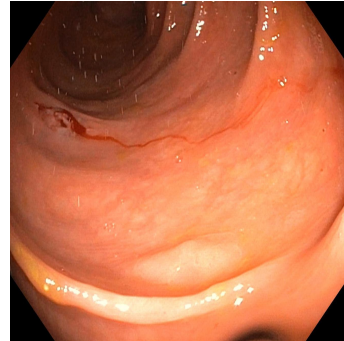
Screening Report (Colonoscopy)



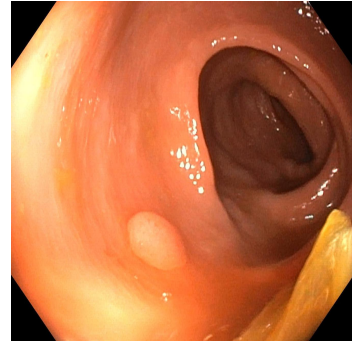
[9] Descending Colon



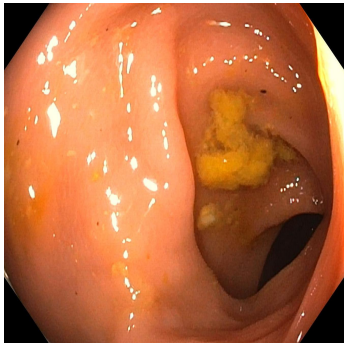
[10] Descending Colon



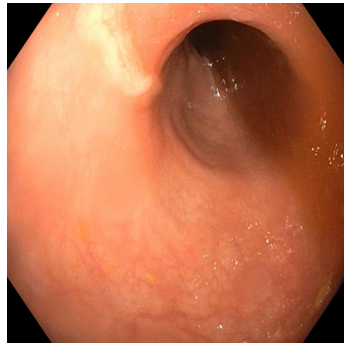
[11] Descending Colon



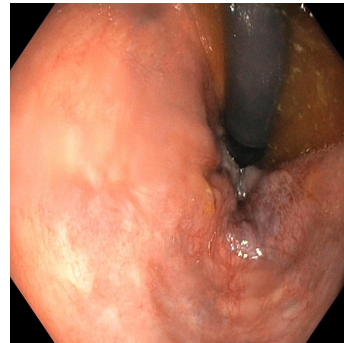
[12] Sigmoid Colon



[13] Sigmoid Colon



[14] Rectum



[15] Anal canal

Signature

พญ.อัญญา เกียรติวิระศักดิ์

Reported by EndoCAPTURE