



โรงพยาบาลไทย

707 ถ. สุรนารายณ์ ตำบล ไทย
อำเภอ ไทย นครราชสีมา 30220

HN : 0116506

Name : นายทองพูน ชนม์สูงเนิน
Age : 01-01-1968 (57 ปี)

AN :

Gender: Male
Location :

โครงการคัดกรองมะเร็งลำไส้
(Colonoscopy Screening)

Operation Date : 17-03-2568 09:52:52
Treatment Coverage :

Screening Report (Colonoscopy)

ENDOSCOPIST

พ.ญ.วิษชุดา กมลอ่อน

ASSISTANTS

N/A

ATTENDENT

PATIENT IN: 09:52:52

OPERATION TIME : 09:52:52 - 10:01:17 (8 Minutes)

WITHDRAWAL TIME : - 10:01:17 (601 Minutes)

INSERTION TIME : 09:52:52 - 00000000 (592 Minutes)

PLACE :

ENDOSCOPE USED : medica SN 00000 [medica]

BRIEF HISTORY : FOBT positive

INDICATION : CRC screening

ANESTHESIA : Topical

MEDICATION : Dormicum
Pethidine

PRE-DIAGNOSTIC : LGIB

BOWEL PREPARATION : Good

TECHNIQUE : None

FINDINGS:

Anal canal: Internal hemorrhoid gr 2
Rectum: Normal
Sigmoid Colon: Pedunculated polyp size 1 cm at 40 cm from AV --> snare polypectomy

Descending Colon: Normal

Splenic flexure: Normal

Transverse Colon: Normal

Hepatic flexure: Normal

Ascending Colon: Normal

Appendiceal Orifice: Normal

Cecum: Normal

Terminal ileum: Normal

POST-DIAGNOSTIC

K635 Colonic polyp

PROCEDURE

4523 Colonoscopy

4542 Polypectomy

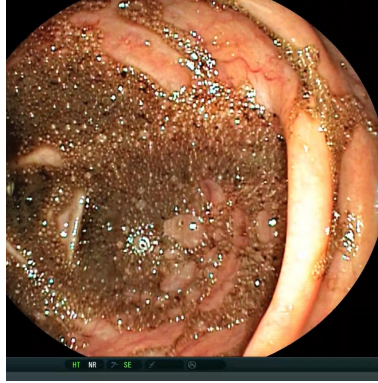
SPECIMEN : polyp at 40 cm from AV 1 Bottle

COMPLICATION : No Immediate Complication

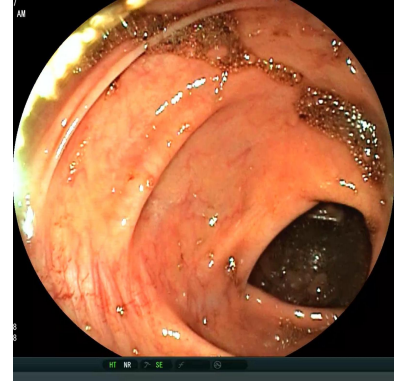ESTIMATED BLOOD LOSS : N/A

BLOOD TRANSFUSION : N/A

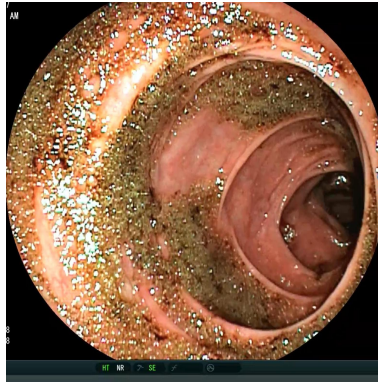
PLAN : N/A



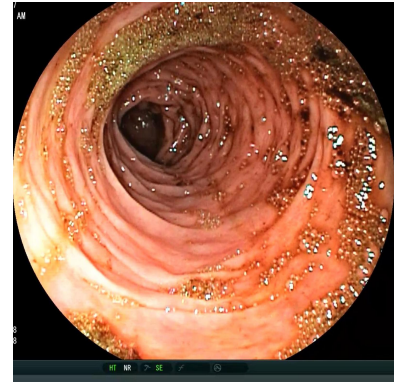
[1]Cecum



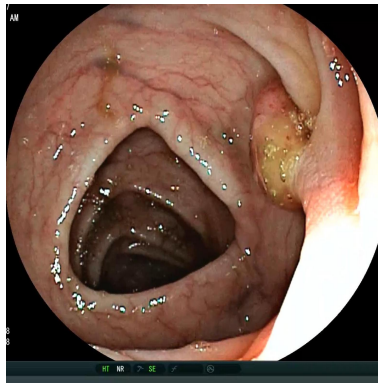
[2]Ascending Colon



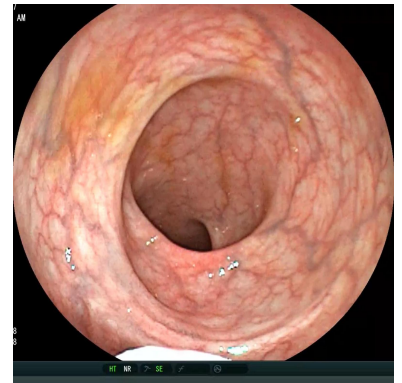
[3]Transverse Colon



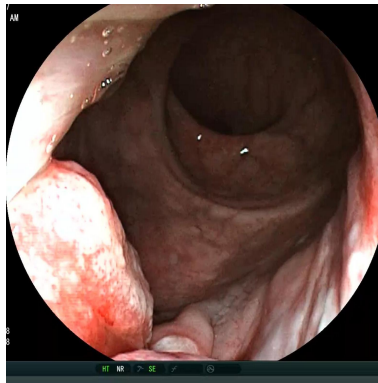
[4]Descending Colon



[5]Sigmoid Colon



[6]Rectum



[7]Anal canal

Signature _____ พ.ญ.วิษชุดา กมลอ่อน

Reported by EndoCAPTURE