



โรงพยาบาลวชิรพยาบาล

198 ถนนโคกกรด-โนนไทย ตำบล  
วชิรพยาบาล อำเภอ วชิรพยาบาล  
นครราชสีมา 30280

HN : 0014321

Name : นางสมทิพ บิสันเตียร  
Age : 01-01-1966 ( 59 ปี )

AN :

Gender: Female  
Location :

โครงการคัดกรองมะเร็งลำไส้  
(Colonoscopy Screening)

Operation Date : 03-03-2568 11:51:11  
Treatment Coverage :

Screening Report (Colonoscopy)

ENDOSCOPIST

ASSISTANTS

ATTENDENT

พญ.พณิตา เพียรษ์

N/A

PATIENT IN: 11:51:11  
OPERATION TIME : 11:51:11 - 11:57:52 ( 6 Minutes )  
WITHDRAWAL TIME : - 11:57:52 (717 Minutes)  
INSERTION TIME : 11:51:11 - 00000000 ( 711 Minutes )  
PLACE :  
ENDOSCOPE USED : medica SN 00000 [medica]  
BRIEF HISTORY : FIT test positive  
INDICATION : CRC screening  
ANESTHESIA : IV sedation  
MEDICATION : N/A  
PRE-DIAGNOSTIC :  
BOWEL PREPARATION : Fair  
TECHNIQUE : CO2 Sufflation

FINDINGS:

Anal canal: Unremarkable  
Rectum: Unremarkable  
Sigmoid Colon: Unremarkable  
Descending Colon: Unremarkable  
Splenic flexure: Unremarkable  
Transverse Colon: Unremarkable  
Hepatic flexure: Unremarkable  
Ascending Colon: Unremarkable  
Appendiceal Orifice: Unremarkable  
Cecum: Unremarkable  
Terminal ileum: Unremarkable

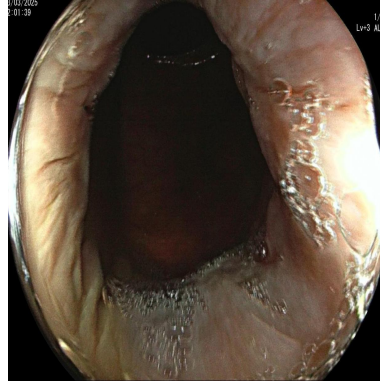
POST-DIAGNOSTIC

Normal Colonoscopy

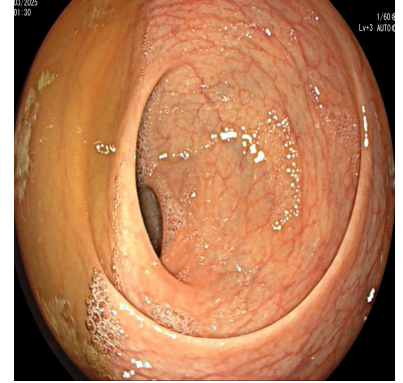
PROCEDURE

None Other Procedure

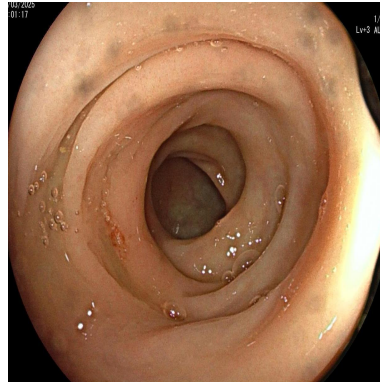
COMPLICATION : None Complication  
ESTIMATED BLOOD LOSS : N/A  
BLOOD TRANSFUSION : N/A  
PLAN : N/A



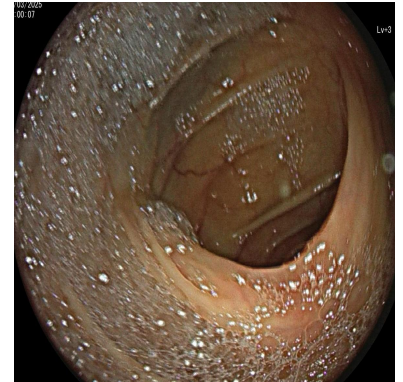
[1]Anal canal



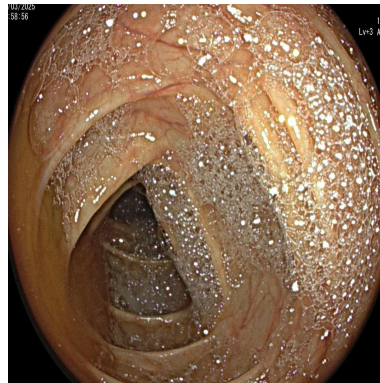
[2]Rectum



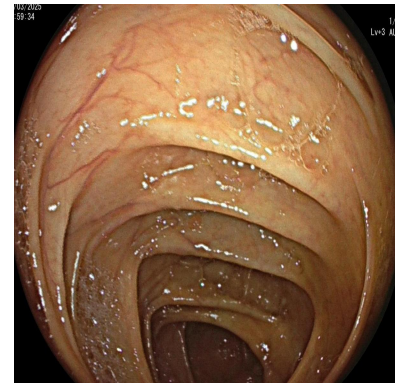
[3]Sigmoid Colon



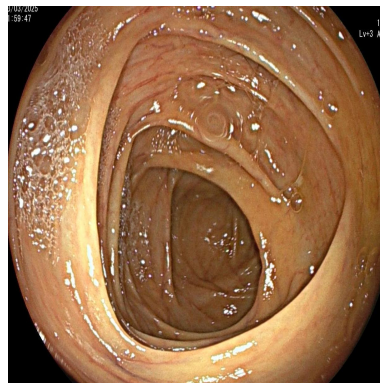
[4]Hepatic flexure



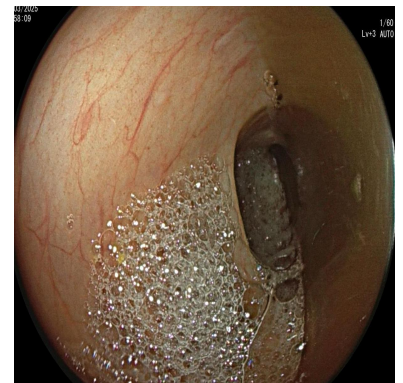
[5]Transverse Colon



[6]Ascending Colon



[7]Cecum



[8]Splenic flexure

Signature

พญ.

พญ.พณิตา เพียรษ์

Reported by EndoCAPTURE