



โรงพยาบาลศิริราช

212 หมู่ 2 มิตรภาพ 212 ถ. มิตรภาพ  
ตำบล มิตรภาพ อำเภอศิริราช นครราชสีมา  
30140

HN : 490120286

Name : นางบัวผัน เทียมคำ  
Age : 01-01-1965 ( 60 ปี )

AN :

Gender: Female  
Location :

โครงการคัดกรองมะเร็งลำไส้  
(Colonoscopy Screening)

Operation Date : 24-03-2568 11:38:28  
Treatment Coverage :

Screening Report (Colonoscopy)

ENDOSCOPIST

พญ.พณิตา เพียรซ์

ASSISTANTS

N/A

ATTENDENT

PATIENT IN: 11:38:28

OPERATION TIME : 11:38:28 - 11:56:10 ( 17 Minutes )

WITHDRAWAL TIME : - 11:56:10 (716 Minutes)

INSERTION TIME : 11:38:28 - 00000000 ( 698 Minutes )

PLACE : Station 1

ENDOSCOPE USED : medica SN 00000 [medica]

BRIEF HISTORY :

INDICATION : Fit Positive

ANESTHESIA : IV sedation

MEDICATION : Dormicum  
Fentanyl

BOWEL PREPARATION : Good

TECHNIQUE : CO2 Sufflation  
Water Exchange

FINDINGS:

- Anal canal: Unremarkable
- Rectum: Unremarkable
- Sigmoid Colon: rectosigmoid colon mass  
20 cm from AV s/p Bx
- Descending Colon: Unremarkable
- Splenic flexure: Unremarkable
- Transverse Colon: Unremarkable
- Hepatic flexure: Unremarkable
- Ascending Colon: Unremarkable
- Appendiceal Orifice: Unremarkable
- Cecum: Unremarkable
- Terminal ileum: Unremarkable

POST-DIAGNOSTIC

rectosigmoid mass 20 cm from AV

PROCEDURE

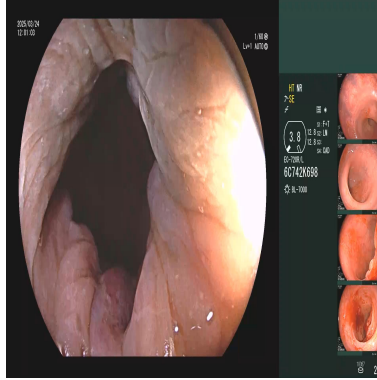
4525 Biopsy

COMPLICATION : None Complication

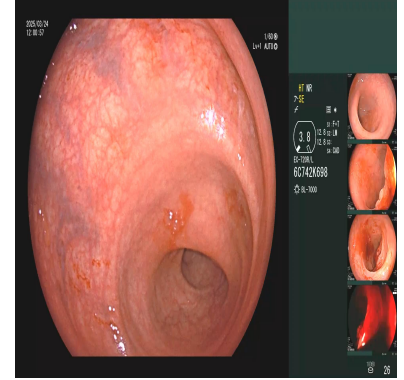
ESTIMATED BLOOD LOSS : 2 ml.

BLOOD TRANSFUSION : - ml.

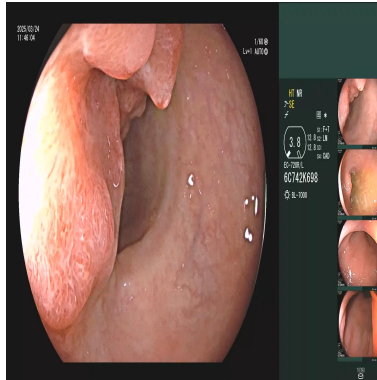
PLAN : N/A



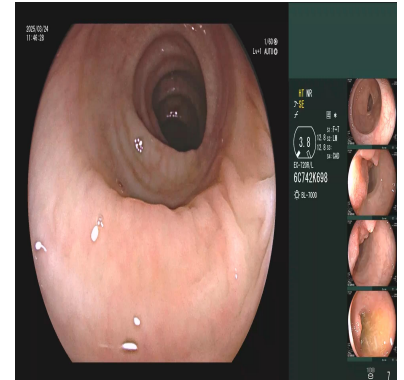
[1]Anal canal



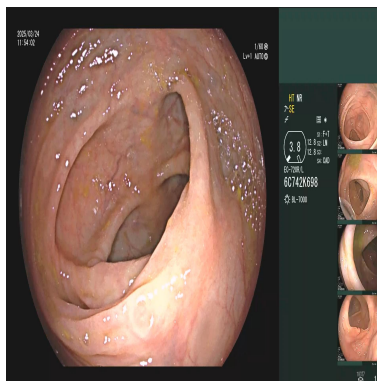
[2]Rectum



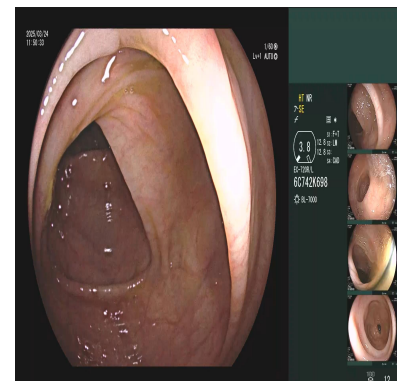
[3]Sigmoid Colon  
rectosigmoid colon 20 cm from AV



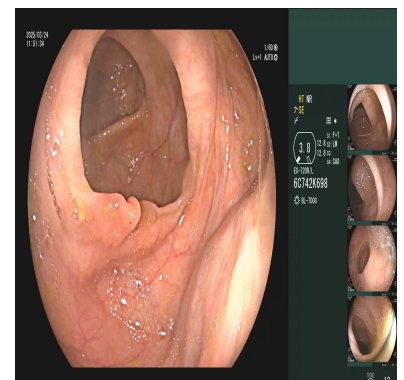
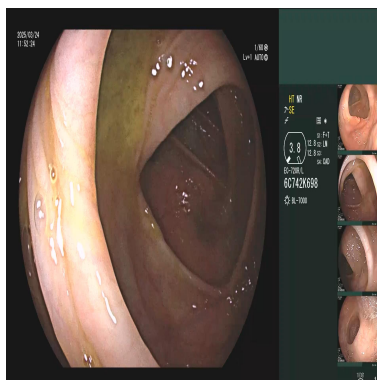
[4]Descending Colon



[5]Splenic flexure



[6]Transverse Colon



Signature \_\_\_\_\_ พญ.พณิตา เพียรซ์

Scum  
Reported by EndoCAPTURE