



โรงพยาบาลศิริราช

42 ตำบล ระแงง อำเภอ ศิริราช สุรินทร์ 32110 044 561 341

HN :10922_000093636

Name : นายสมพร ดีสม
Age : 01-01-1960 (65 ปี)

AN :

Gender: Male

Location :

Equipment : medica

หน่วยส่องกล้องทางเดินอาหาร

(Digestive Endoscopy Department)

Operation Date : 01-02-2568 14:32:25

Treatment Coverage :

Digestive Endoscopy Report (Colonoscopy)

ENDOSCOPIST

พญ.พิชชา เหลืองเจริญทิพย์

ASSISTANTS

N/A

ATTENDENT

นพ.ธีรพันธ์ ทองกรณ์

PATIENT IN: 14:31:35

OPERATION TIME : 14:32:25 - 14:39:04 (6 Minutes)

WITHDRAWAL TIME : 14:37:20 - 14:39:04 (1 Minutes)

INSERTION TIME : 14:32:25 - 14:37:20 (4 Minutes)

PLACE :

ENDOSCOPE USED : medica SN 00000 [medica]

BRIEF HISTORY : fit test positive

INDICATION : CRC screening

ANESTHESIA : TIVA

MEDICATION : N/A

PRE-DIAGNOSTIC :

BOWEL PREPARATION : Fair

TECHNIQUE : None

FINDINGS:

Anal canal:	Normal
Rectum:	Normal
Sigmoid Colon:	Normal
Descending Colon:	Normal
Splenic flexure:	Normal
Transverse Colon:	Normal
Hepatic flexure:	Normal
Ascending Colon:	Normal
Appendiceal Orifice:	Normal
Cecum:	Normal
Terminal ileum:	Normal

POST-DIAGNOSTIC

Normal Colonoscopy

PROCEDURE

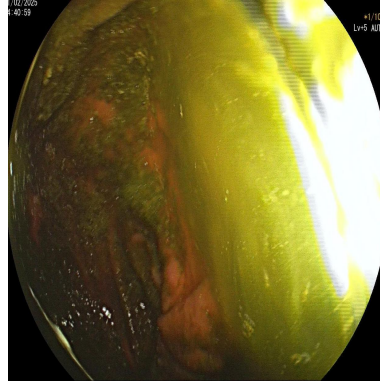4523 Colonoscopy

COMPLICATION : None Complication

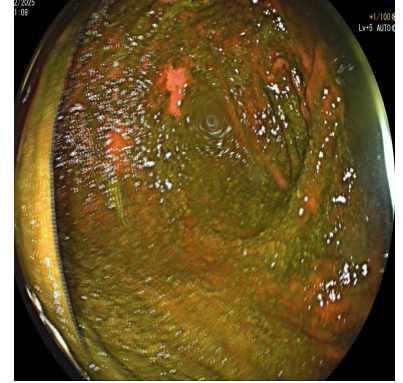
ESTIMATED BLOOD LOSS : N/A

BLOOD TRANSFUSION : N/A

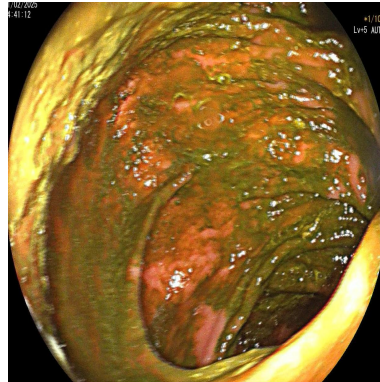
PLAN : N/A



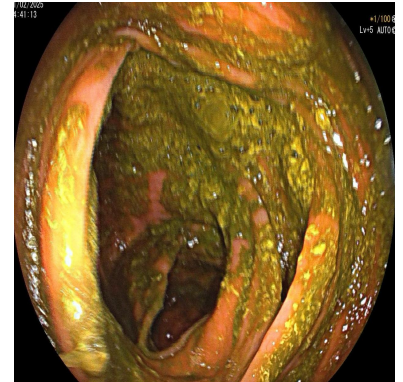[1]



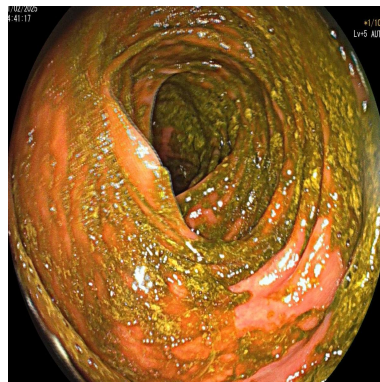
[2]



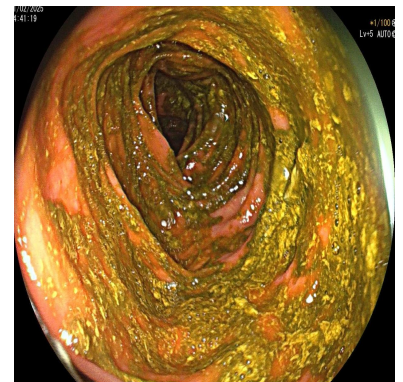
[3]



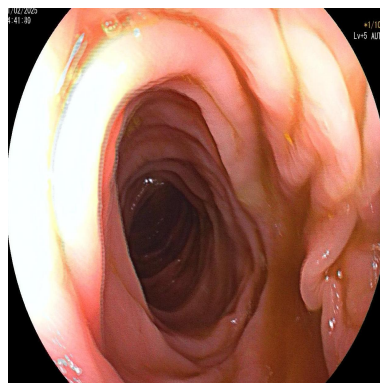
[4]



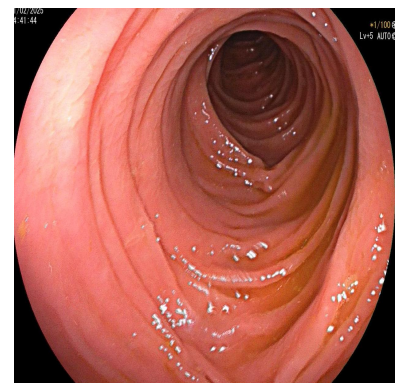
[5]



[6]



[7]



[8]

Signature

พญ.พิชชา เหลืองเจริญทิพย์

Reported by EndoINDEX



โรงพยาบาลศิริราช

42 ตำบล ระแงง อำเภอ ศิขรภูมิ สุรินทร์
32110 044 561 341

HN :10922_000093636

Name : นายสมพร ดิสม
Age : 01-01-1960 (65 ปี)

Operation Date : 01-02-2568 14:32:25
Treatment Coverage :

AN :

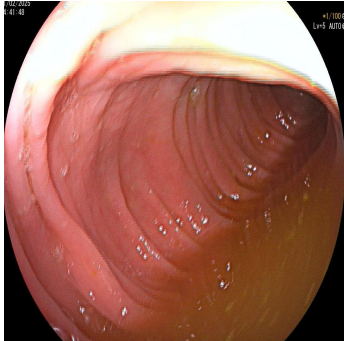
Gender: Male

Location :

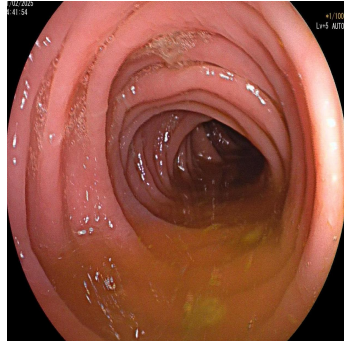
Equipment : medica

หน่วยส่องกล้องทางเดินอาหาร
(Digestive Endoscopy Department)

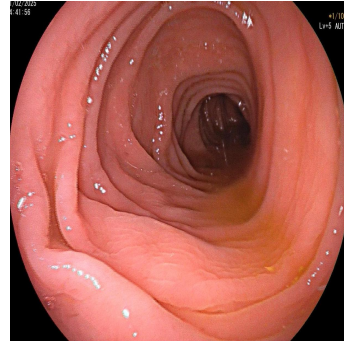
Digestive Endoscopy Report (Colonoscopy)



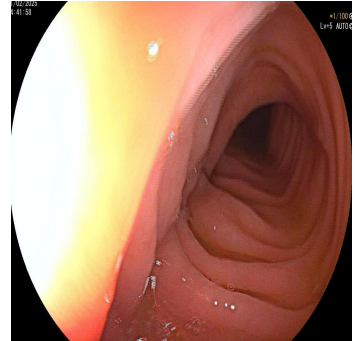
[9]



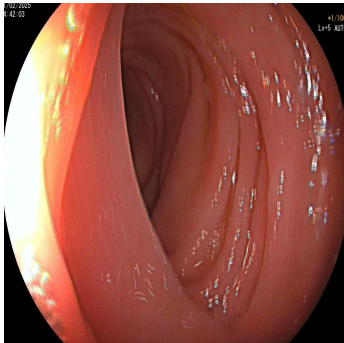
[10]



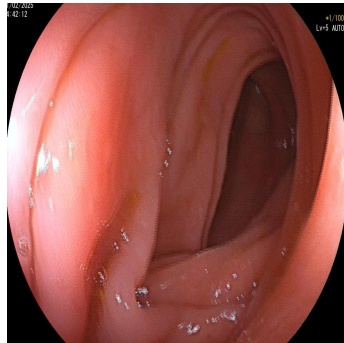
[11]



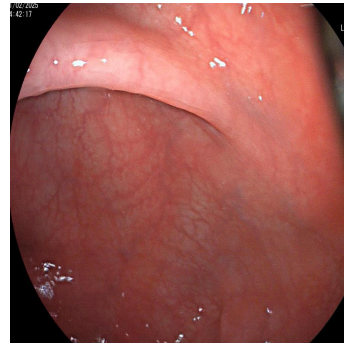
[12]



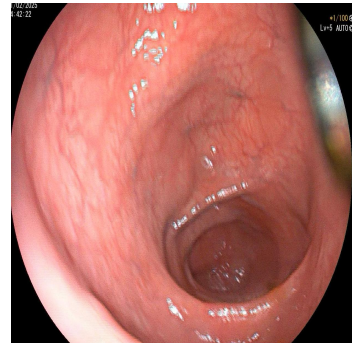
[13]



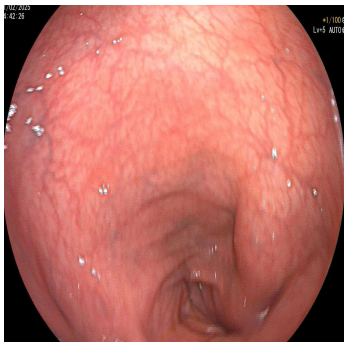
[14]



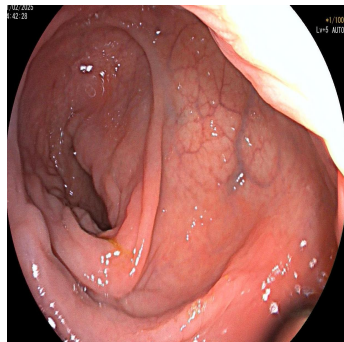
[15]



[16]



[17]



[18]

Signature

พญ.พิชชา เหลืองเจริญทิพย์

Reported by EndoINDEX