



โรงพยาบาลสังขะ

700 ถนนสารคาม ตำบลสังขะ อำเภอสังขะ จังหวัดสุรินทร์ 32150

HN : 000304690

Name : นายเคียน เต็มทอง

Gender : ชาย

Age : 66 ปี

Operation Date : 19-04-2568 (14:35:32)

### โครงการคัดกรองมะเร็งลำไส้ (Colonoscopy Screening) Screening Report (Colonoscopy)

**ENDOSCOPIST**

นพ.ชยพล สุขโต

**ASSISTANTS**

N/A

**ATTENDENT**

**PATIENT IN:** 14:35:30

**OPERATION TIME :** 14:35:32 - 15:32:42 ( 57 Minutes )

**WITHDRAWAL TIME :** 15:32:33 - 15:32:42 ( 0 Minutes )

**INSERTION TIME :** 14:35:32 - 15:32:33 ( 57 Minutes )

**PLACE :**

**ENDOSCOPE USED :** medica SN 00000 [medica]

**BRIEF HISTORY :** Fit +

**INDICATION :** Fit Positive

**ANESTHESIA :** N/A

**MEDICATION :** N/A

**PRE-DIAGNOSTIC :**

**BOWEL PREPARATION :** Poor

**TECHNIQUE :** None

**FINDINGS:**

**Anal canal:** Normal

**Rectum:** Normal

**Sigmoid Colon:** polyp 0.5 cm. at 20 cm.

**Descending Colon:** Normal

**Splenic flexure:** Normal

**Transverse Colon:** pedunculated polyp 0.5 cm. at 60 cm.

**Hepatic flexure:** Normal

**Ascending Colon:** Normal

**Appendiceal Orifice:** Normal

**Cecum:** Normal

**Terminal ileum:** Normal

**POST-DIAGNOSTIC**

**K635 Colonic polyp**

**PROCEDURE**

**4542 Polypectomy**

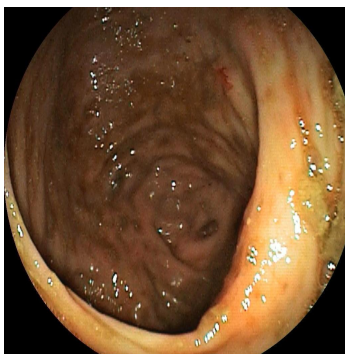**SPECIMEN :** polyp 2 Bottle

**COMPLICATION :** None Complication

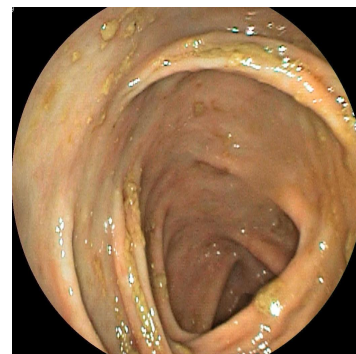
**ESTIMATED BLOOD LOSS :** N/A

**BLOOD TRANSFUSION :** N/A

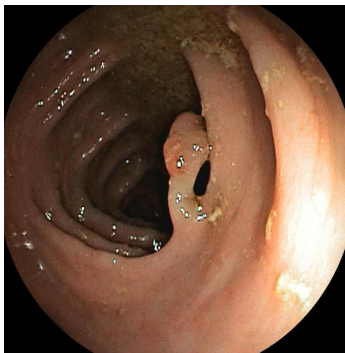
**PLAN :** N/A



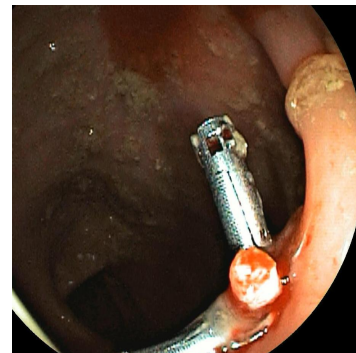
[1]



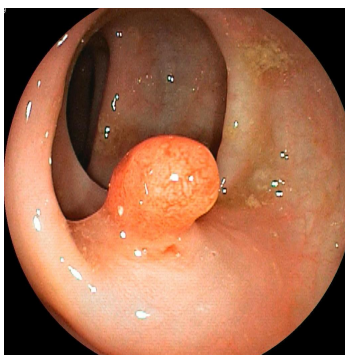
[2]



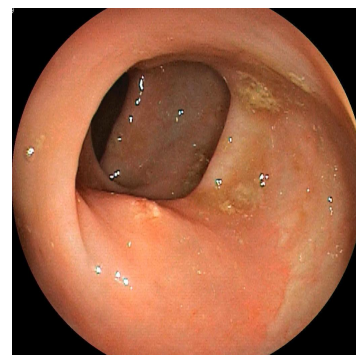
[3]



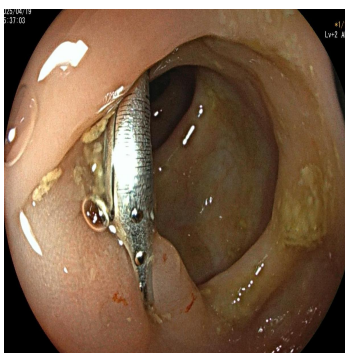
[4]



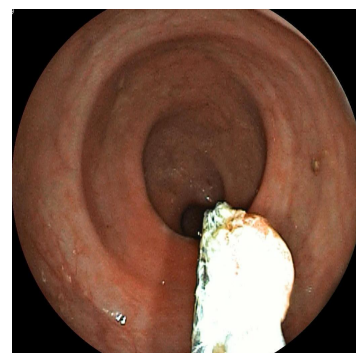
[5]



[6]



[7]



[8]

Signature

นพ.ชยพล สุขโต

Reported by EndoCAPTURE