



โรงพยาบาลสังขะ

700 ถนนสารคาม ตำบลสังขะ อำเภอสังขะ จังหวัดสุรินทร์ 32150

HN : 000304690

Name : นายเคียน เต็มทอง

Gender : ชาย

Age : 66 ปี

Operation Date : 19-04-2568 (14:35:32)

โครงการคัดกรองมะเร็งลำไส้ (Colonoscopy Screening) Screening Report (Colonoscopy)

ENDOSCOPIST

นพ.ชยพล สุขโต

ASSISTANTS

N/A

ATTENDENT

PATIENT IN: 14:35:30

OPERATION TIME : 14:35:32 - 15:32:42 (57 Minutes)

WITHDRAWAL TIME : 15:32:33 - 15:32:42 (0 Minutes)

INSERTION TIME : 14:35:32 - 15:32:33 (57 Minutes)

PLACE :

ENDOSCOPE USED : medica SN 00000 [medica]

BRIEF HISTORY : Fit +

INDICATION : Fit Positive

ANESTHESIA : N/A

MEDICATION : N/A

PRE-DIAGNOSTIC :

BOWEL PREPARATION : Poor

TECHNIQUE : None

FINDINGS:

Anal canal: Normal

Rectum: Normal

Sigmoid Colon: polyp 0.5 cm. at 20 cm. form AV

Descending Colon: Normal

Splenic flexure: Normal

Transverse Colon: pedunculated polyp 0.5 cm. at 60 cm.

Hepatic flexure: Normal

Ascending Colon: Normal

Appendiceal Orifice: Normal

Cecum: Normal

Terminal ileum: Normal

POST-DIAGNOSTIC

K635 Colonic polyp

PROCEDURE

4542 Polypectomy

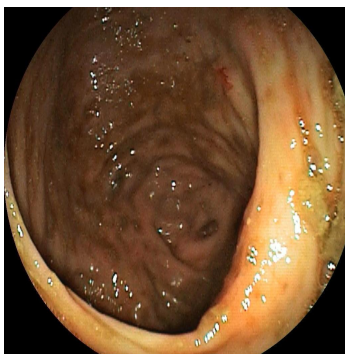SPECIMEN : polyp 2 Bottle

COMPLICATION : None Complication

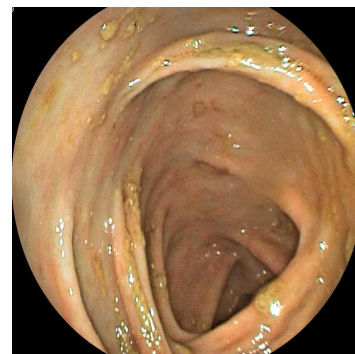ESTIMATED BLOOD LOSS : N/A

BLOOD TRANSFUSION : N/A

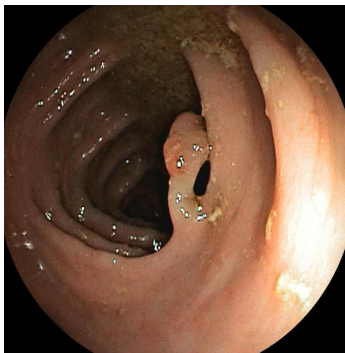
PLAN : N/A



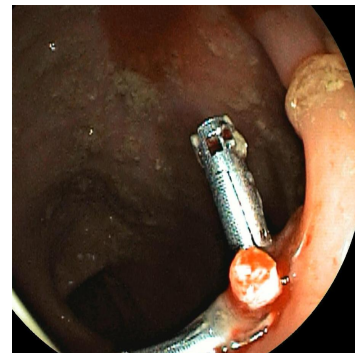
[1]



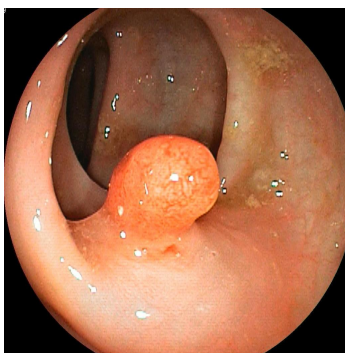
[2]



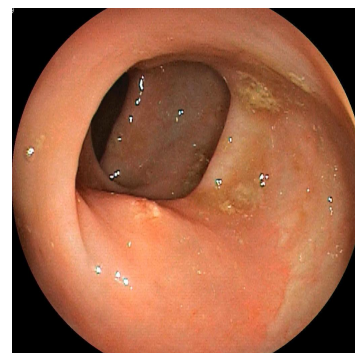
[3]



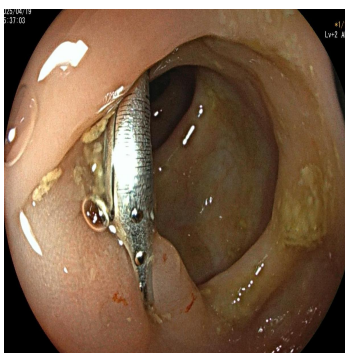
[4]



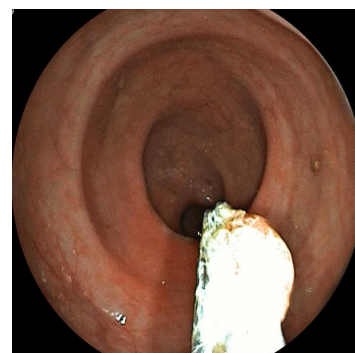
[5]



[6]



[7]



[8]

Signature

นพ.ชยพล สุขโต

Reported by EndoCAPTURE