



โรงพยาบาลโพธิ์ประทับช้าง

128 ถ.โพธิ์ประทับช้าง-ไพศาล หมู่ 2 ตำบล/แขวง โพธิ์ประทับช้าง อำเภอ/เขต  
โพธิ์ประทับช้าง จังหวัด พิจิตร 66190

HN : 000012902

Name : นางกมลวรส ทาพ

Gender : หญิง

Age : 57 ปี

Operation Date : 02-07-2568 (12:48:50)

### โครงการคัดกรองมะเร็งลำไส้ (Colonoscopy Screening)

### Screening Report (Colonoscopy)

**ENDOSCOPIST**

พญ.อิชฎาพร พานเทียน

**ASSISTANTS**

N/A

**ATTENDENT**

**PATIENT IN:** 12:48:50

**OPERATION TIME :** 12:48:50 - 13:06:05 ( 17 Minutes )

**WITHDRAWAL TIME :**

**INSERTION TIME :**

**PLACE :**

**ENDOSCOPE USED :** medica SN 00000 [medica]

**BRIEF HISTORY :**

**INDICATION :** Fit Positive

**ANESTHESIA :** N/A

**MEDICATION :** Propofol 60 mg.

Dormicum 1.5 mg.

Fentanyl 25 mcg.

**Boston Bowel Prep Score :** B (SUCCESS)

**BOWEL PREPARATION :** None

**TECHNIQUE :** CO2 Sufflation

**FINDINGS:**

**Anal canal:** Normal

**Rectum:** Normal

**Sigmoid Colon:** Normal

**Descending Colon:** Normal

**Splenic flexure:** Normal

**Transverse Colon:** Normal

**Hepatic flexure:** Normal

**Ascending Colon:** Polyp 0.5 cm > polypectomy

**Appendiceal Orifice:** Normal

**Cecum:** Normal

**Terminal ileum:** Normal

**POST-DIAGNOSTIC**

K635 Colonic polyp

**PROCEDURE**

4523 Colonoscopy

4836 EMR

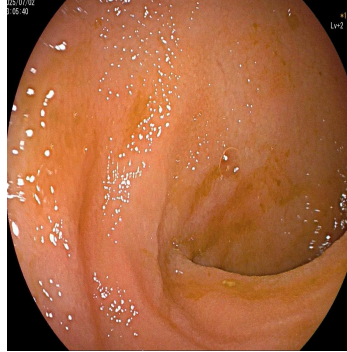
**SPECIMEN :** Ascending polyp Bottle

**COMPLICATION :** No Immediate Complication

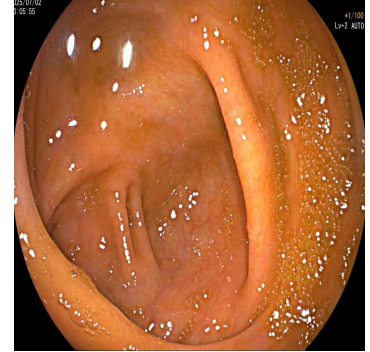
**ESTIMATED BLOOD LOSS :** N/A

**BLOOD TRANSFUSION :** N/A

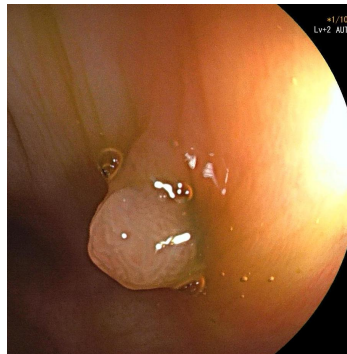
**PLAN :** N/A



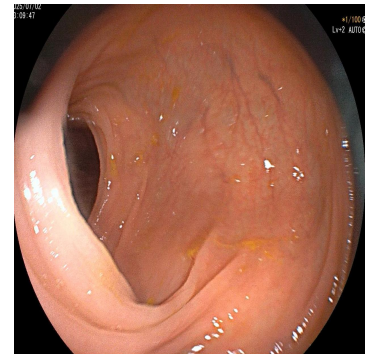
[1]Terminal ileum



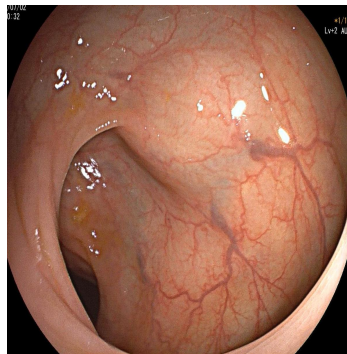
[2]Cecum



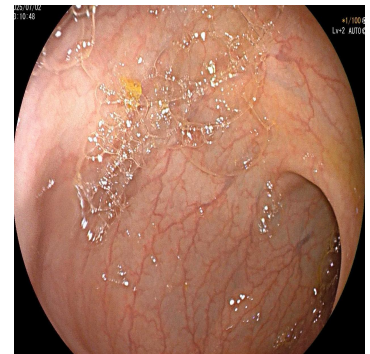
[3]Ascending Colon



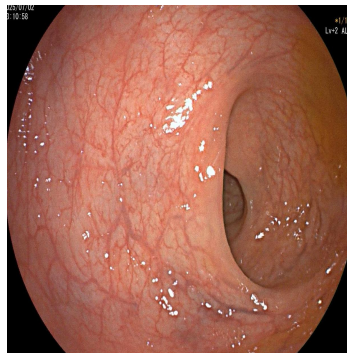
[4]Transverse Colon



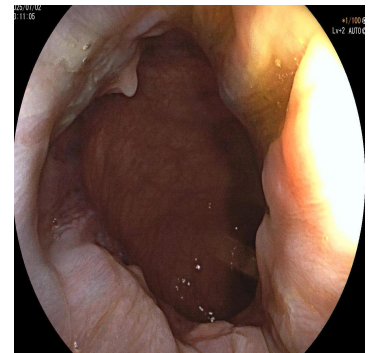
[5]Descending Colon



[6]Sigmoid Colon



[7]Rectum



[8]Anal canal

Signature

พญ.อิชฎาพร พานเทียน

Reported by EndoCAPTURE