



โรงพยาบาลวชิรรมารมี

HN : 0001989

AN :

1 หมู่ที่ 13 ตำบล บ้านนา อำเภอลำลูกกา จังหวัดปทุมธานี
พ.จ.ร. 66140

Name : นายเทพ อ้นอินทร์
Age : 01-01-1970 (55 ปี)

Gender: Male
Location :

โครงการคัดกรองมะเร็งลำไส้
(Colonoscopy Screening)

Operation Date : 27-03-2568 14:40:02
Treatment Coverage :

Screening Report (Colonoscopy)

ENDOSCOPIST

พญ.อิชฎาพร พานเทียน

ASSISTANTS

N/A

ATTENDENT

PATIENT IN: 14:40:02

OPERATION TIME : 14:40:02 - 15:10:49 (30 Minutes)

WITHDRAWAL TIME : - 15:10:49 (910 Minutes)

INSERTION TIME : 14:40:02 - 00000000 (880 Minutes)

PLACE : Station 1

ENDOSCOPE USED : medica SN 00000 [medica]

BRIEF HISTORY : FIT test +

INDICATION : CRC screening

ANESTHESIA : IV sedation

MEDICATION : Propofol 40 mg.

Dormicum 1.5 mg.

Fentanyl 25 mcg.

PRE-DIAGNOSTIC : FIT test +

BOWEL PREPARATION : Good swiff

TECHNIQUE : CO2 Sufflation

FINDINGS:

Anal canal: Normal

Rectum: Polyp 0.8 cm > Polypectomy

Sigmoid Colon: Normal

Descending Colon: Normal

Splenic flexure: Polyp 0.5 cm > polypectomy

Transverse Colon: Normal

Hepatic flexure: Normal

Ascending Colon: Normal

Appendiceal Orifice: Normal

Cecum: Normal

Terminal ileum: Normal

POST-DIAGNOSTIC

K635 Colonic polyp

PROCEDURE

4523 Colonoscopy

4542 Polypectomy

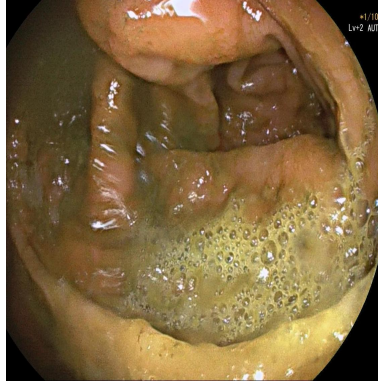Adrenalin injection 2 ml.

COMPLICATION : No Immediate Complication

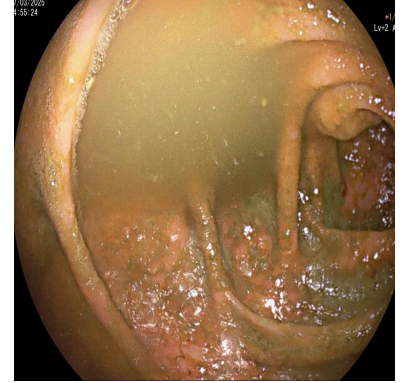
ESTIMATED BLOOD LOSS : N/A

BLOOD TRANSFUSION : N/A

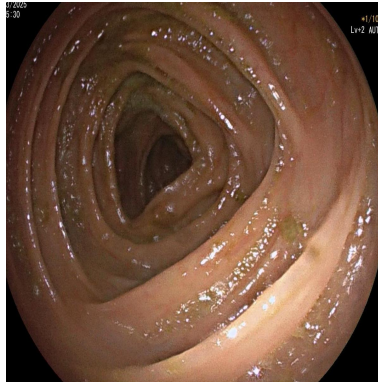PLAN : N/A



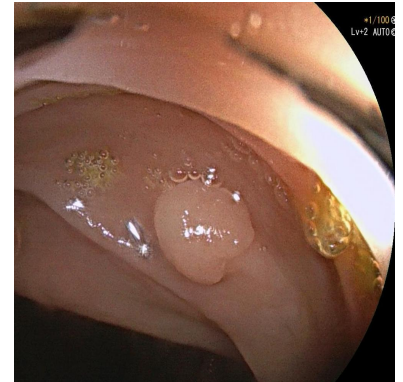
[1]Cecum



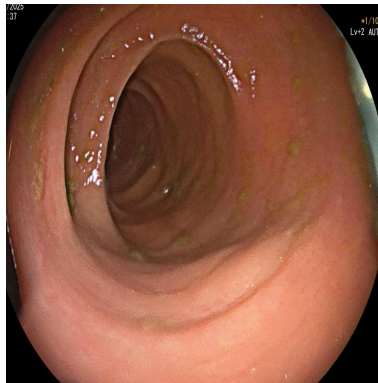
[2]Ascending Colon



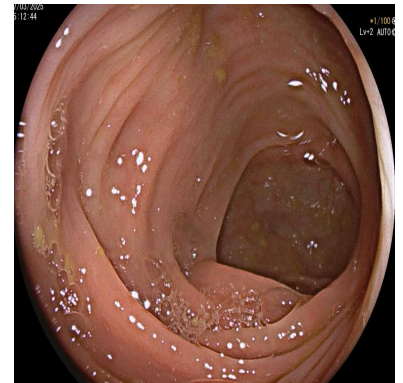
[3]Transverse Colon



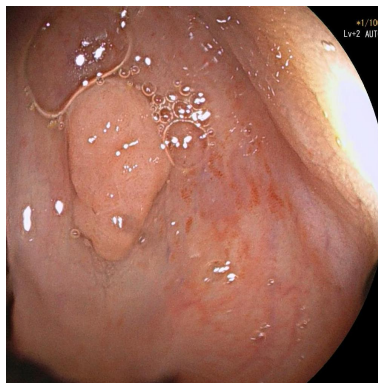
[4]Splenic flexure



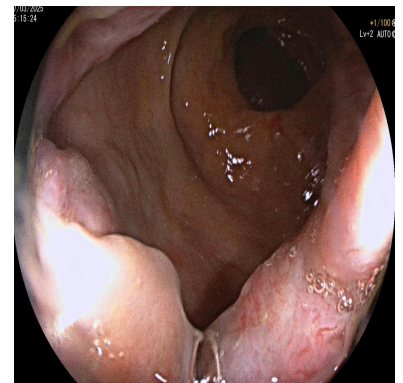
[5]Descending Colon



[6]Sigmoid Colon



[7]Rectum



[8]Anal canal

Signature _____ พญ.อิชฎาพร พานเทียน

Reported by EndoCAPTURE