



โรงพยาบาลวชิรสารมี

HN : 0009952

AN :

1 หมู่ที่ 13 ตำบล บ้านนา อำเภอลำลูกกา จังหวัด ปทุมธานี รหัสไปรษณีย์ 10130

Name : นางแดง นานแดง
Age : 01-01-1972 (53 ปี)

Gender: Female
Location :

โครงการคัดกรองมะเร็งลำไส้
(Colonoscopy Screening)

Operation Date : 27-03-2568 10:56:09
Treatment Coverage :

Screening Report (Colonoscopy)

ENDOSCOPIST

พญ.อิชฎาพร พานเทียน

ASSISTANTS

N/A

ATTENDENT

PATIENT IN: 10:56:09

OPERATION TIME : 10:56:09 - 11:06:30 (10 Minutes)

WITHDRAWAL TIME : - 11:06:30 (666 Minutes)

INSERTION TIME : 10:56:09 - 00000000 (656 Minutes)

PLACE : Station02

ENDOSCOPE USED : medica SN 00000 [medica]

BRIEF HISTORY : FIT test +

INDICATION : CRC screening

ANESTHESIA : IV sedation

MEDICATION : Propofol 40 mg.
Dormicum 1 mg.
Pethidine 50 mg.

PRE-DIAGNOSTIC : FIT test +

BOWEL PREPARATION : Good Swiff

TECHNIQUE : CO2 Sufflation

FINDINGS:

| | |
|-----------------------------|--------|
| Anal canal: | Normal |
| Rectum: | Normal |
| Sigmoid Colon: | Normal |
| Descending Colon: | Normal |
| Splenic flexure: | Normal |
| Transverse Colon: | Normal |
| Hepatic flexure: | Normal |
| Ascending Colon: | Normal |
| Appendiceal Orifice: | Normal |
| Cecum: | Normal |
| Terminal ileum: | Normal |

POST-DIAGNOSTIC

Normal Colonoscopy

PROCEDURE

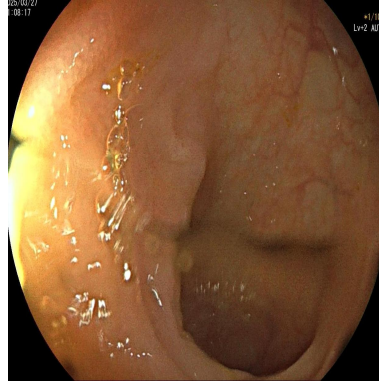
4523 Colonoscopy

COMPLICATION : No Immediate Complication

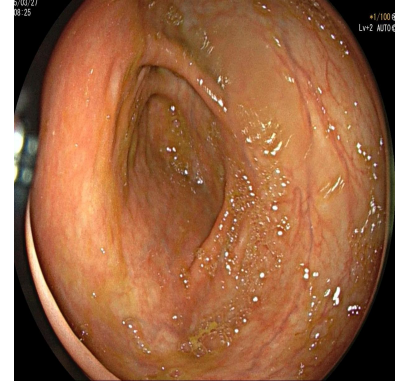
ESTIMATED BLOOD LOSS : N/A

BLOOD TRANSFUSION : N/A

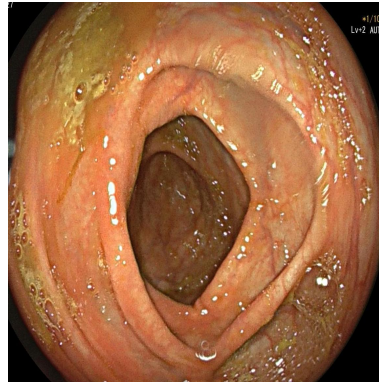
PLAN : N/A



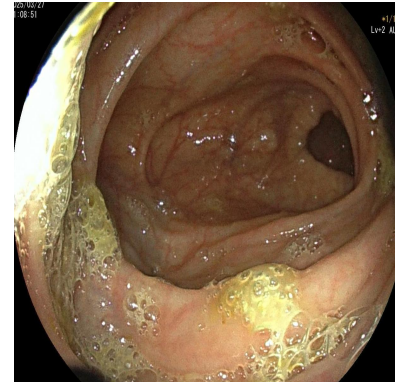
[1]Terminal ileum



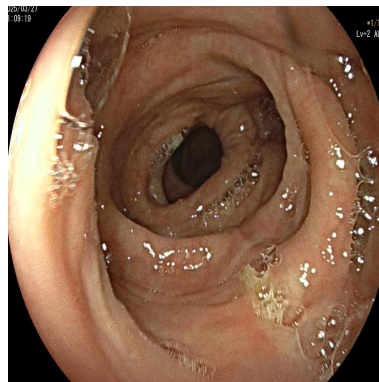
[2]Cecum



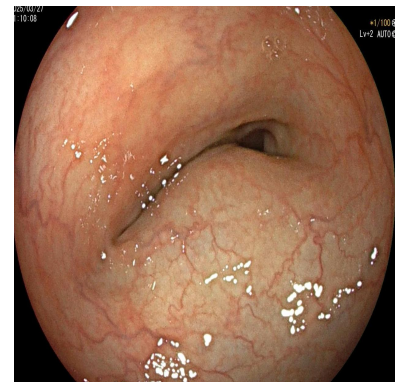
[3]Ascending Colon



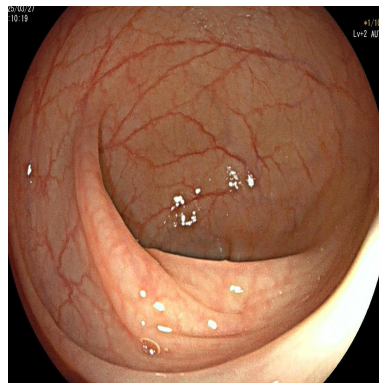
[4]Transverse Colon



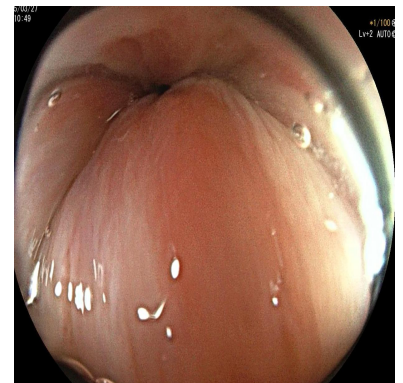
[5]Descending Colon



[6]Sigmoid Colon



[7]Rectum



[8]Anal canal

Signature

พญ.อิชฎาพร พานเทียน

Reported by EndoCAPTURE