



โรงพยาบาลมะเร็งชลบุรี  
หมู่ที่ 2 300 ตำบล เสม็ด  
อำเภอเมืองชลบุรี ชลบุรี 20000

HN : 1598-68

Name : นางสาวอานะสิทธิ์ ศัลยพงษ์

Age : 01-01-1975 ( 50 ปี )

Operation Date : 03-04-2568 09:21:30

Treatment Coverage :

AN :

Gender: Female

Location :

โครงการคัดกรองมะเร็งลำไส้

(Colonoscopy Screening)

Screening Report (Colonoscopy)

**ENDOSCOPIST**

พ.ชัชยุทธ สิงห์นิยม

**ASSISTANTS**

N/A

**ATTENDENT**

**PATIENT IN:** 09:21:30

**OPERATION TIME :** 09:21:30 - 09:37:43 ( 16 Minutes )

**WITHDRAWAL TIME :**

**INSERTION TIME :**

**PLACE :**

**ENDOSCOPE USED :** medica SN 00000 [medica]

**BRIEF HISTORY :** CRC screening

**INDICATION :** CRC screening

**ANESTHESIA :** IV sedation

**MEDICATION :** N/A

**PRE-DIAGNOSTIC :**

**BOWEL PREPARATION :** Excellent

**TECHNIQUE :** None

**FINDINGS:**

**Anal canal:** Normal

**Rectum:** Normal

**Sigmoid Colon:** Pedunculated polyp size 0.5 cm at 30 cm from AV --- polypectomy with hemoclip

**Descending Colon:** Normal

**Splenic flexure:** Normal

**Transverse Colon:** Normal

**Hepatic flexure:** Normal

**Ascending Colon:** Normal

**Appendiceal Orifice:** Normal

**Cecum:** Normal

**Terminal ileum:** Normal

**POST-DIAGNOSTIC**

Colonic polyp at sigmoid colon

**PROCEDURE**

4523 Colonoscopy

4542 Polypectomy

Hemoclip 1 pcs.

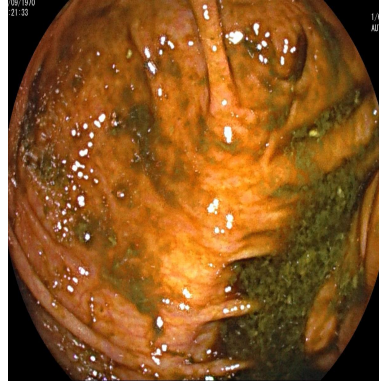
**SPECIMEN :** polyp at 30 cm from av (sigmoid colon) Bottle

**COMPLICATION :** No Immediate Complication

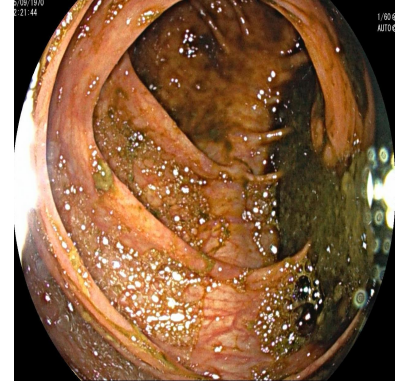
**ESTIMATED BLOOD LOSS :** - ml.

**BLOOD TRANSFUSION :** - ml.

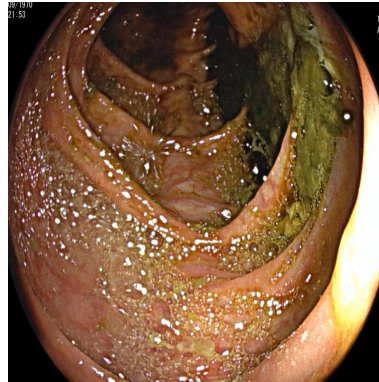
**PLAN :** N/A



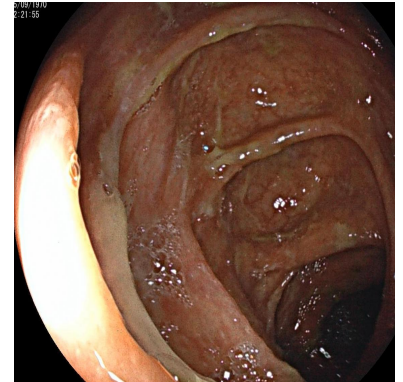
[1]Cecum



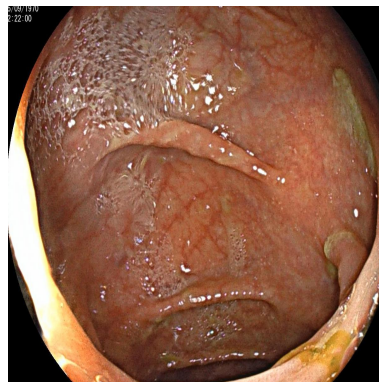
[2]Ascending Colon



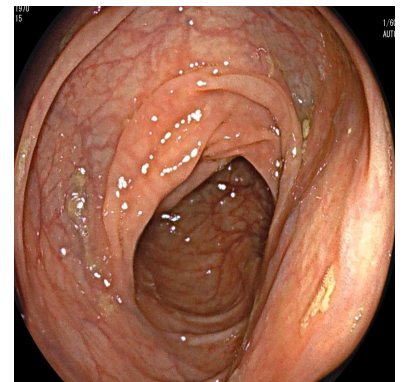
[3]Hepatic flexure



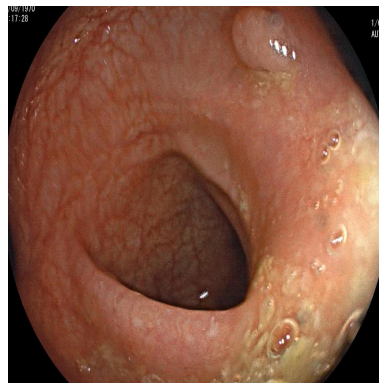
[4]Transverse Colon



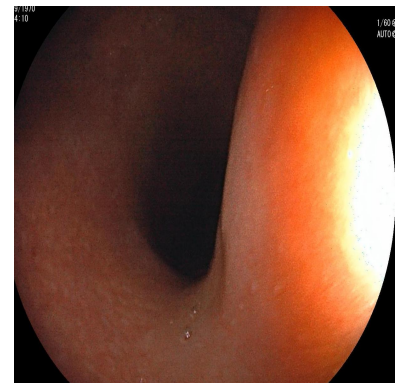
[5]Splenic flexure



[6]Descending Colon



[7]Sigmoid Colon



[8]Rectum

Signature \_\_\_\_\_ พ.ชัชยุทธ สิงห์นิยม

Reported by EndoCAPTURE